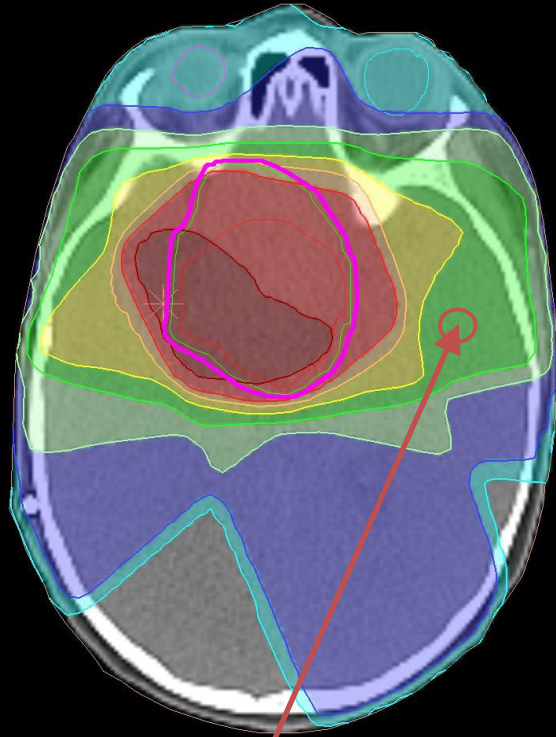
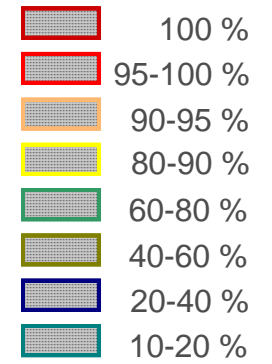


# Röntgen



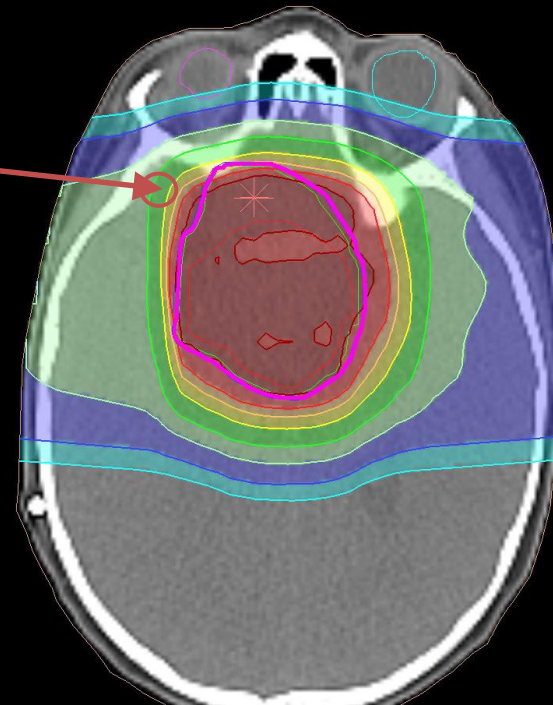
## Dosisbereiche



Zielgebiet pink umrandet

gleicher  
Dosisbereich

# Protonen



Fallbeispiel:  
Optikusgliom  
7 Jahre  
CT des Schädels